

Insert to


September 2017

CRST EUROPE

Cataract & Refractive Surgery Today

THE IC-8 IOL

Incorporating a simple physical principle to extend depth of focus for a broad spectrum of patients.



Sponsored by

AcuFocus[™]

Understanding Small-Aperture Optics3

Why monocular does not mean monovision.

BY JOHN A. VUKICH, MD

Extending Depth of Focus for Cataract Patients5

European study results showed that the IC-8 IOL provided excellent distance and intermediate vision in addition to good near vision.

BY H. BURKHARD DICK, MD, PhD

Integrating a Small-Aperture IOL Into Routine Clinical Practice7

Overall, the IC-8 IOL is a great option to add to one's premium IOL armamentarium for the treatment of presbyopia.

BY TESS HUYNH, MBBS, FRANZCO

The View of the Posterior Segment With a Small-Aperture IOL9

With the IC-8 IOL, one can still reliably perform retinal assessments and procedures.

BY SATHISH SRINIVASAN, MD

A Small-Aperture IOL in Post-Refractive Surgery Patients..... 11

The IC-8 IOL can be used successfully in post-RK eyes.

BY RAVI SINGH, MD

Simplifying Astigmatism Correction 13

The small-aperture optic design of the IC-8 IOL is more tolerant of cylinder than monofocal and trifocal IOLs.

BY ROBERT EDWARD ANG, MD

The Challenge of Keratoconus in Cataract Surgery and the Benefits of a Small-Aperture IOL 15

Patients with keratoconus have responded positively to the IC-8 IOL.

BY OMID KERMANI, MD

Understanding Small-Aperture Optics

Why monocular does not mean monovision.

BY JOHN A. VUKICH, MD



The IC-8 IOL (AcuFocus; Figure 1) incorporates the novel use of an optical principle that has been recognized since antiquity. The use of a pinhole to correct refractive errors surfaced in Roman times, when it was first described that a small hole in an olive leaf could correct visual disturbances. Certainly, even before then, Chinese philosophers had talked about the properties of a small hole in the restoration of vision, and even Leonardo da Vinci had sketched it in his codex.

As the first and only true depth of focus IOL to be developed, the IC-8 lens is implanted in the nondominant eye of patients, and a standard monofocal lens is typically implanted in the dominant eye. Other extended depth of focus IOL technologies use optical aberrations to flatten the depth of focus, but the IC-8 lens incorporates a pinhole to collimate light rays to reach the retina through the central aperture. The small-aperture design blocks the peripheral defocused (and often aberrated) rays from disrupting the image and flattens the defocus curve on both the myopic and hyperopic sides, providing extended depth of focus in both slightly

hyperopic and slightly myopic patients. That flattening of the curve essentially leaves patients with a small amount of myopia, which helps them to appreciate the full benefit of the extended depth of focus provided by the IC-8 lens.

CONTINUOUS AND UNINTERRUPTED VISION

At plano, the small-aperture optic of the IC-8 IOL provides about 2.50 D of continuous extended depth of focus in the functional range. Small-aperture optics can be leveraged to provide additional near benefit by shifting the defocus curve slightly to the minus. When the eye that receives the IC-8 IOL is targeted for a small amount of residual myopia (-0.75 D) to shift the defocus curve, the result is further enhancement of near vision without degrading distance vision. This effectively extends the range of vision to nearly 3.00 D of uninterrupted, continuous extended depth of focus (Figure 2) as opposed to that provided by multifocal or trifocal lens designs, which have pronounced peaks and valleys.

As seen in Figure 3, the IC-8 IOL provides better image resolution across a broader range of defocus than monofocal and trifocal lenses. This helps patients experience a more natural range




Figure 1. The IC-8 IOL.

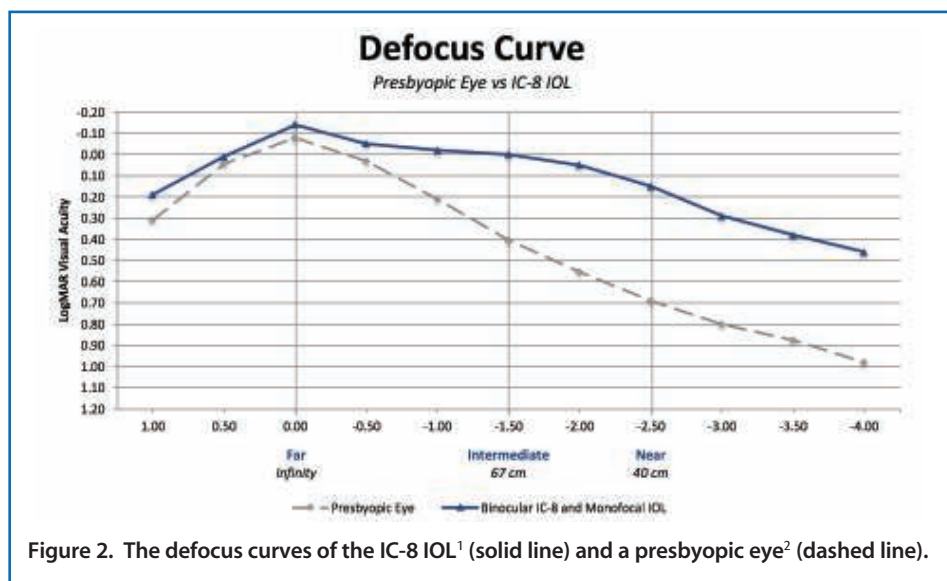


Figure 2. The defocus curves of the IC-8 IOL¹ (solid line) and a presbyopic eye² (dashed line).

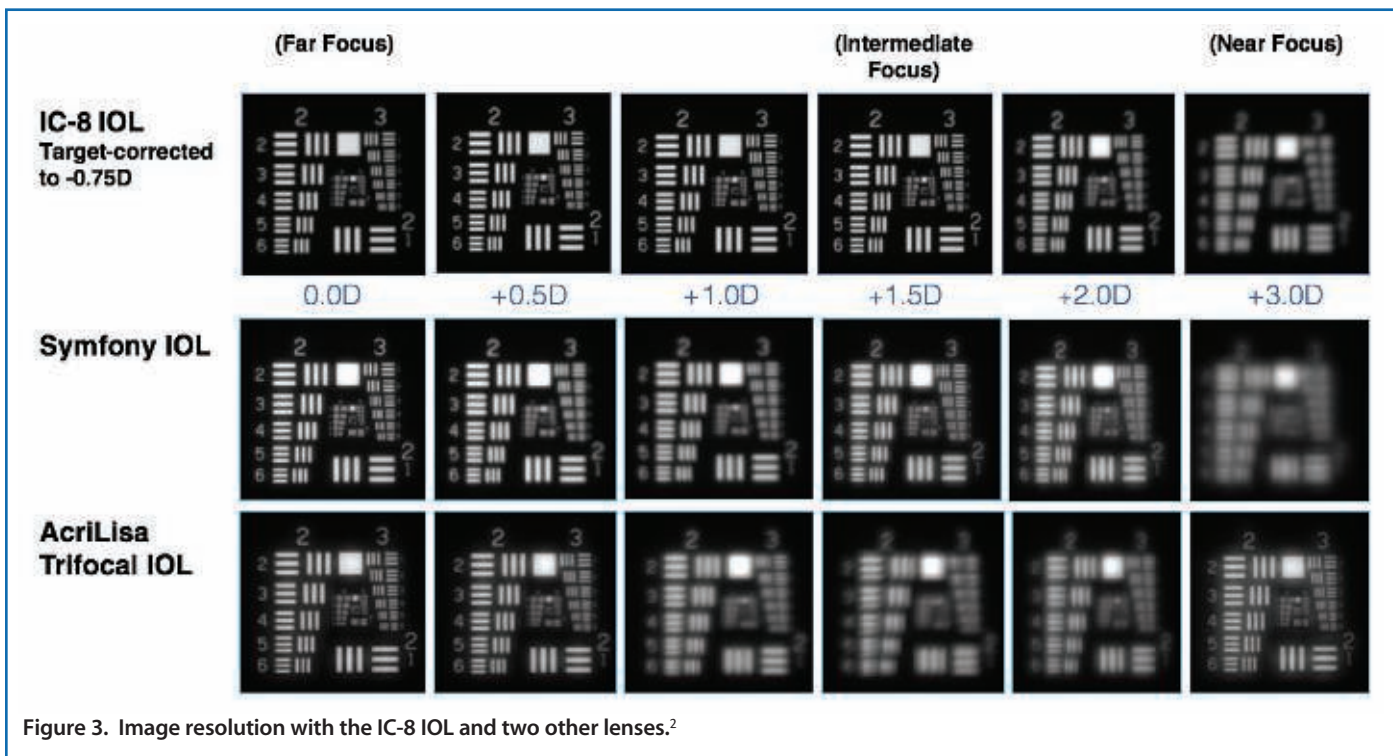


Figure 3. Image resolution with the IC-8 IOL and two other lenses.²

of vision like they had when they were in their 30s and could effortlessly see from near to far without the frustration of blurry and clear vision zones.

This approach to vision correction may be confused with monovision, as the IC-8 IOL eye is targeted for slight myopia (-0.75 D) and the fellow eye for plano; however, the difference in the target refractions actually helps patients maximize the benefit of the IC-8 IOL to extend depth of focus rather than to improve only one focus at the detriment of another. Although the refractive strategy for each eye may be monocularly unique, patients still maintain excellent binocular vision and stereopsis.

A FORGIVING LENS

Another benefit of the IC-8 small-aperture IOL is that it is very forgiving. Due to the unique extended depth of focus design, we can be slightly off on our attempted versus achieved refraction and the patient still obtains excellent distance vision. Additionally and importantly, a pinhole will also negate up to about 1.50 D cylinder.

These are unique and positive attributes of the IC-8 IOL in that it is inherently optically forgiving of small misses in the attempted target refraction. What that translates into is a larger landing zone—a larger sweet spot that makes this lens easy to use and easy for the patient to accept. The IC-8 IOL

gives surgeons a great level of confidence that they can reliably provide patients with continuous, uninterrupted vision.

CONCLUSION

The IC-8 IOL helps patients to achieve good intermediate and near depths of focus while giving up almost nothing at distance. As a result, quality of vision with the IC-8 IOL is the same from near to intermediate to distance, which is unlike multifocal or trifocal implants that have a blurry transition between the focal points.

A multicenter clinical trial of the IC-8 IOL was recently completed in Europe,¹ and an investigational device trial is planned for the United States. I am greatly encouraged by the results my colleagues in Europe have had, and I look forward to when this lens is available for our patients in the United States. ■

1. Dick HB, et al. Prospective multicenter trial of a small-aperture intraocular lens in cataract surgery. *J Cataract Refract Surg.* 2017;43:956-968.

2. Data on file, Acufocus, Inc.

John A. Vukich, MD

- Surgical Director, David Duehr Dean Center for Refractive Surgery, Madison, Wisconsin
- javukich@gmail.com
- Financial disclosure: Consultant (AcuFocus)

Extending Depth of Focus for Cataract Patients

European study results showed that the IC-8 IOL provided excellent distance and intermediate vision in addition to good near vision.

BY H. BURKHARD DICK, MD, PhD



The pinhole effect on vision has been well documented and dates back more than 400 years. Simply stated, vision through a pinhole allows only a small amount of focused central light rays to enter the eye, preventing the unfocused rays in the periphery from reaching the retina. This phenomenon results in better uncorrected visual acuity and depth of vision.

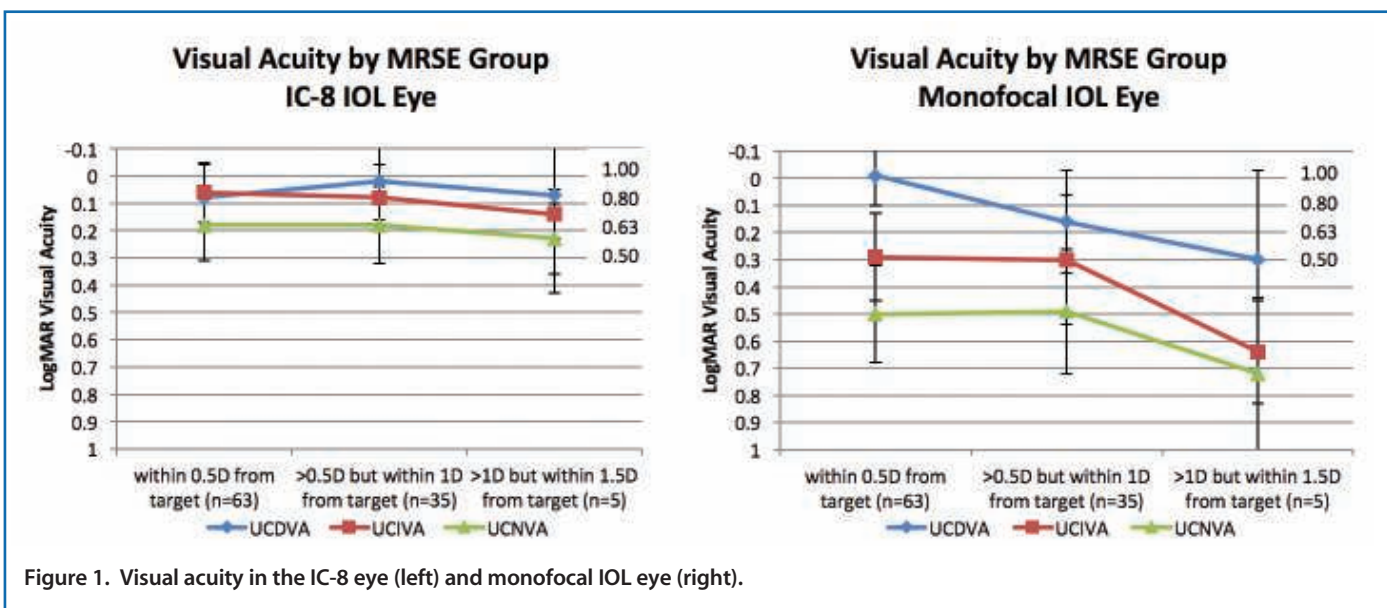
We all know that the Kamra corneal inlay (AcuFocus) uses the pinhole effect as means to treat presbyopia with excellent results. The central aperture in the inlay has no power and provides an unobstructed pathway for focused light to reach the retina. Building on this concept, the company designed an IOL operating on the same principle. This small-aperture lens, the IC-8 IOL, received CE Mark approval in September 2014. It is also approved in Australia and New Zealand. We recently

participated in a multicenter clinical trial of the IC-8 IOL,¹ and in this article I report these results as well as my personal experience with this lens.

EARLY RESULTS

Twelve European sites across Germany, Austria, Spain, Italy, Belgium, and Norway participated in a prospective clinical trial of the IC-8 IOL. A total of 108 patients were enrolled in the study. In all cases, the IC-8 IOL was implanted in the nondominant eye, and an aspheric monofocal IOL was implanted in the dominant eye.

With both eyes corrected to plano, patients achieved 2.25 D of continuous functional vision, but when the eye that received the IC-8 IOL was corrected to -0.75 D and the monofocal eye was corrected to plano, patients achieved 2.75 D of continuous functional vision with no appreciable loss of distance visual



CHECK IT OUT

The complete data report on the European study of the IC-8 IOL can be found in the July issue of the *Journal of Cataract and Refractive Surgery*:

Dick HB, et al. Prospective multicenter trial of a small-aperture intraocular lens in cataract surgery. *J Cataract Refract Surg.* 2017;43:956-968.

At 6 months postoperative, the IC-8 IOL eyes tolerated up to a deviation of ± 1.00 D from the target refraction without an appreciable change in visual acuity at all distances (Figure 1). It was also able to tolerate up to 1.50 D corneal cylinder (Figure 2), a degree of error that is not well tolerated with a monofocal or multifocal IOL. In the study, the IC-8 small-aperture IOL eyes achieved a mean MRSE of -0.42 D, compared to 0.01 D in the aspheric monofocal IOL eyes. As a result, monocular distance, intermediate, and near UCVA in the IC-8 IOL eye was 0.87 , 0.83 , and 0.66 , respectively (Figure 3). With the IC-8 IOL target corrected to -0.75 D, binocular UCVA was even more impressive at 1.20 , 0.95 , and 0.71 for distance, intermediate, and near vision, respectively (Figure 4).

We also determined that binocular contrast sensitivity with the IC-8 IOL was equivalent to that of the monofocal IOL eye; however, a slight decrease in mesopic contrast sensitivity did occur with the IC-8 IOL eye.

CONCLUSION

After cataract surgery in routine and complex cases alike, UCVA can be improved and depth of focus can be reliably extended with the IC-8 IOL. In the European study,¹ and in my personal experience with more than 120 cases, I have found the visual acuity results to be excellent, with the small-aperture optic compensating for corneal residual astigmatism and refractive error.

In conclusion, the IC-8 IOL provides patients with high-quality distance and intermediate vision and good near vision, with no change in binocular contrast sensitivity. ■

1. Dick HB, et al. Prospective multicenter trial of a small-aperture intraocular lens in cataract surgery. *J Cataract Refract Surg.* 2017;43:956-968.

H. Burkhard Dick, MD, PhD

- Director and Chairman, University Eye Hospital, Bochum, Germany
- burkhard.dick@kk-bochum.de
- Financial disclosure: Consultant, Guest Lecturer (AcuFocus)

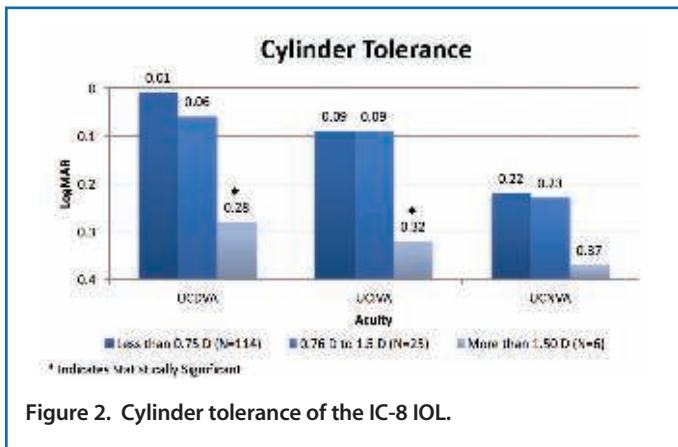


Figure 2. Cylinder tolerance of the IC-8 IOL.

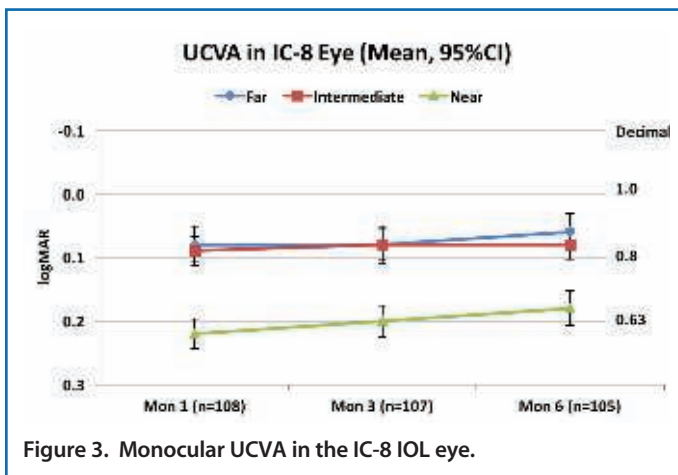


Figure 3. Monocular UCVA in the IC-8 IOL eye.

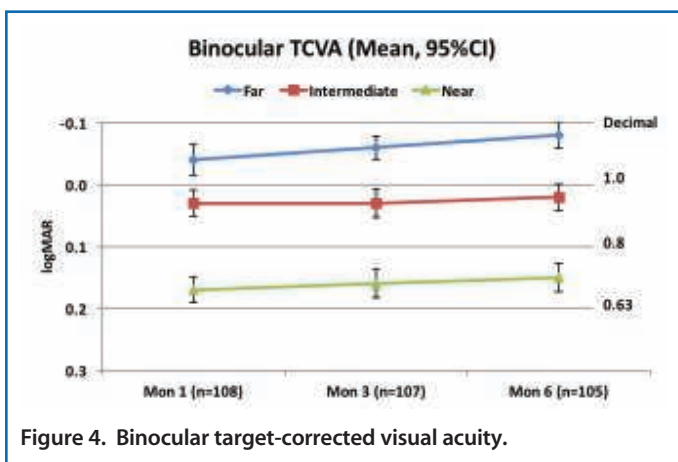


Figure 4. Binocular target-corrected visual acuity.

acuity. As a result, we now select a target refraction of -0.75 D in the eye receiving the IC-8 IOL; this helps patients achieve the maximal depth of focus range.

Integrating a Small-Aperture IOL Into Routine Clinical Practice

Overall, the IC-8 IOL is a great option to add to one's premium IOL armamentarium for the treatment of presbyopia.

BY TESS HUYNH, MBBS, FRANZCO



In recent years, I have seen an increasing frequency of postrefractive surgery patients presenting for cataract surgery. In this population, nailing the refractive target is most crucial. The two essential components of achieving this are IOL selection and accurate calculation of IOL power.

Although I typically implant premium IOLs in a large proportion of my cataract patients, I am not as keen to implant them in postrefractive surgery patients, as these patients tend to be less tolerant of visual side effects such as glare and halos. One option that has been effective in postrefractive surgery patients, among other patient groups, is the IC-8 lens (AcuFocus). This small-aperture monofocal IOL applies the same optical principle as the Kamra corneal inlay (AcuFocus) in that it incorporates a nondiffractive opaque mask and a central aperture into the optic in order to create a pinhole effect. This pinhole effect extends the depth of focus, producing excellent visual outcomes across a wide range of working distances. For my post-LASIK patients who have previously enjoyed spectacle freedom for their daily activities, the IC-8 IOL can maintain clear distance vision without loss of their intermediate and near vision. This strategy can be simulated with a pinhole in the consulting room to illustrate the optical principle to patients.

GENERAL CATARACT PATIENTS

I have also found that the small-aperture optics of the IC-8 IOL can be beneficial to the general cataract patient. Although not monovision, those who can adapt to monovision are well suited to this lens option. It is an ideal lens for these patients because it is implanted in their reading eye, which helps them to achieve good near vision and supports a continuous and uninterrupted range of vision once they have learned to adapt.

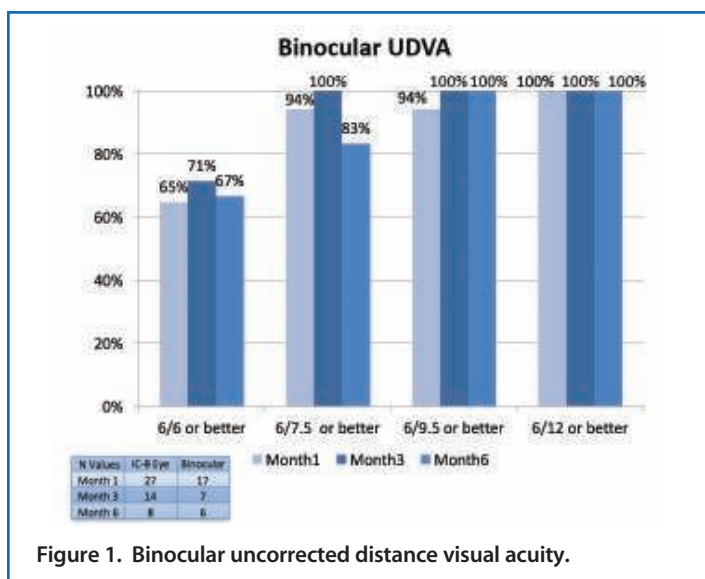


Figure 1. Binocular uncorrected distance visual acuity.

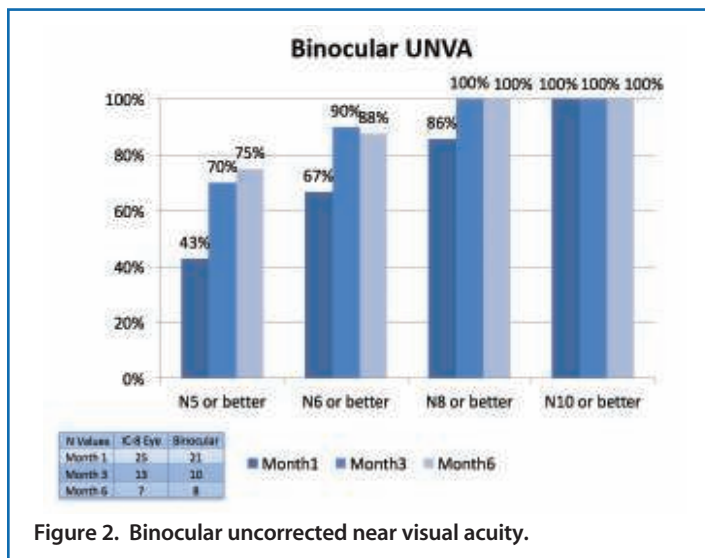
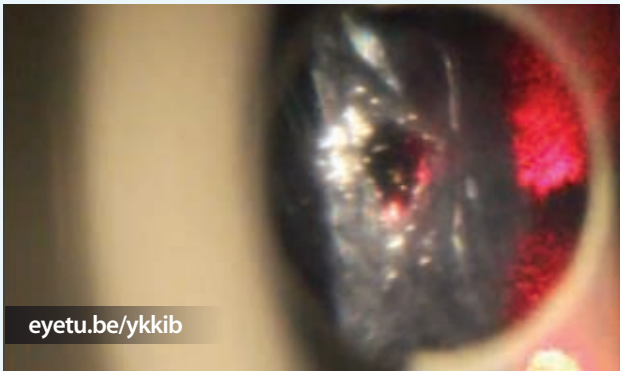


Figure 2. Binocular uncorrected near visual acuity.



WATCH IT NOW

Performing a YAG capsulotomy in an eye implanted with the IC-8 IOL.



In my early clinical experience with the IC-8 lens, I have been focusing on patients who would not be happy to compromise their distance vision. These patients tend to be myopes who usually adapt to monovision without much difficulty. They are used to sharp vision in their dominant eye, rely on intermediate vision for things like computer work, and are already familiar with monovision. I still prefer to implant multifocal IOLs in hyperopic patients and those who find binocularity is important.

INTEGRATION

The key strengths of the IC-8 lens are that it extends the depth of focus and that it provides good near and intermediate vision without compromising far vision. Another strength of the lens is that it is highly forgiving when the target refraction is not met—something that can be extremely beneficial in postrefractive surgery patients. It is also a great choice in those with corneal irregularities or iris defects.

Integration of the IC-8 IOL into my clinical practice has been fairly easy, and surgery involves only minor adjustments to my technique. The IC-8 lens is a thicker lens, so it is slightly more difficult to handle and requires a larger incision (3.2–3.5 mm) than other IOLs. However, both require only a short learning curve to overcome.

I continue to base my IOL choice on patient preferences and lifestyles; however, I am finding more and more that the IC-8 lens is an appropriate choice for a variety of patients who would otherwise have fewer options to correct their presbyopia. I have found that, when I target the right patient group, postoperative results are excellent.

The right patient for the IC-8 lens includes those who have:

- Undergone prior refractive surgery;
- High expectations and demands for excellent quality of vision for intermediate and distance;
- Higher-order aberrations or corneal irregularities;
- Had ocular trauma or inflammation causing iris defects;
- A monofocal IOL in one eye and desire to have their second eye treated with a premium solution; or
- Corneal astigmatism of 1.50 D or less.

CLOSING THOUGHTS

I have been using the IC-8 IOL for about 8 months and have implanted it unilaterally in about 40 patients. At 6 months after implantation of the IC-8 IOL in one eye and a monofocal lens in the other, 100% of my patients achieved a binocular UDVA of 20/30 or better (Figure 1) and a binocular UNVA of N8 or better (Figure 2).

Integrating the IC-8 lens into clinical practice has been straightforward, and the benefits to both patients and the practice are worth considering. ■

Tess Huynh, MBBS, FRANZCO

- iVISION CLINIC, New South Wales, Australia
- drtesshuynh@gmail.com
- Financial disclosure: None acknowledged

The View of the Posterior Segment With a Small-Aperture IOL

With the IC-8 IOL, one can still reliably perform retinal assessments and procedures.

BY SATHISH SRINIVASAN, MD



The IC-8 IOL (AcuFocus) is an aspheric monofocal hydrophobic IOL with modified C-haptics and an embedded 5- μ m thick small-aperture mask inside the 6-mm optic that is designed to provide a continuous and uninterrupted range of distance, intermediate, and near vision. The mask is made of polyvinylidene fluoride and carbon nanoparticles, with an aperture of 1.36 mm, a total diameter of 3.23 mm, and 3,200 microperforations.

The IC-8 IOL is implanted monocularly, in the nondominant eye. In my own experience, which includes 16 eyes, four of which were in patients who had previously undergone laser vision correction and one of whom was a post-RK patient, the mean UDVA in the IC-8 IOL eye was 20/27. In all cases, I used a target refraction of -0.75 D in the IC-8 IOL eye while the fellow dominant eye was targeted for emmetropia with a monofocal or a monofocal toric IOL. We have found that these targets produce a mean refractive spherical equivalent of -0.50 D postoperatively and improve near vision better than a target of plano. Postoperatively, binocular UNVA in this patient population was about 20/25.

Patients tend to have fewer visual side effects like halos, glare, and starbursts with the IC-8 IOL compared with the other presbyopia-correcting IOLs that use diffractive optics. Further, post-laser vision correction and post-RK eyes seem to do well with the enhanced depth of focus technology provided by the small aperture. Having the IC-8 IOL implanted in the non-dominant eye and a standard monofocal or monofocal toric IOL implanted in the dominant eye provides transitional vision between distance, intermediate, and near. Patients who are already used to a monovision strategy do well with the IC-8 lens, and to date in my experience patient satisfaction has been high.

RETINAL ASSESSMENTS ARE POSSIBLE

One of the primary questions in my mind when I started implanting the IC-8 IOL was: Does the lens interfere with the view of the posterior segment? In order to determine this, we recently conducted a small study of five patients who received the IC-8 IOL in their nondominant eye and were phakic or had a monofocal IOL in their dominant eye. Bilateral fundus examination with a nonmydriatic fundus camera, 24-2 Humphrey visual field test (Carl Zeiss Meditec), and OCT of both optic nerve heads and the macula were performed postoperatively. In all cases, the mask in the IC-8 IOL did not obstruct the view of the posterior segment.

When looking through the viewfinder of the fundus camera, the mask of the IC-8 IOL was visible (Figure 1). Although the peripheral light scattering caused by the natural lens was visible on the fundus photograph of the phakic eye (Figure 2), it was not on the photograph of the IC-8 IOL eye (Figure 3). This is because the mask blocked the aberrations from the fundus view. Further, with the IC-8 IOL in situ there were no problems getting an uninterrupted view of the posterior pole and optic nerve head (Figure 4).

CASE STUDY

One patient in the cohort developed culture-negative endophthalmitis 3 weeks following an uncomplicated refractive

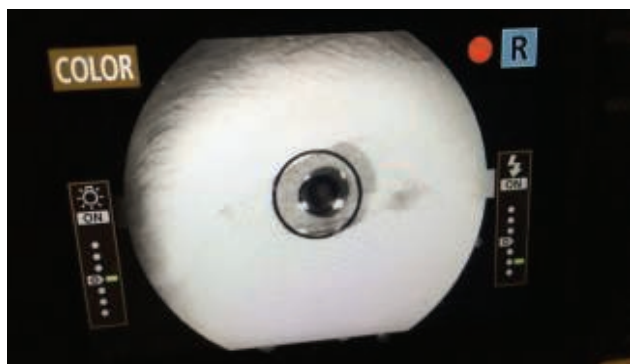


Figure 1. The mask of the IC-8 IOL is visible through the viewfinder of the fundus camera.

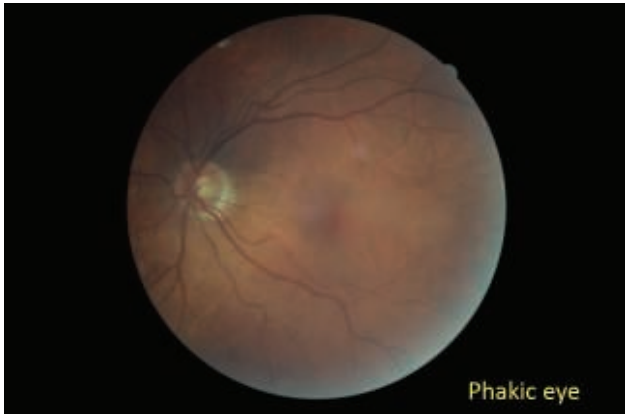

Figure 2. Fundus photograph depicting the peripheral light scattering caused by the natural lens of a phakic eye.

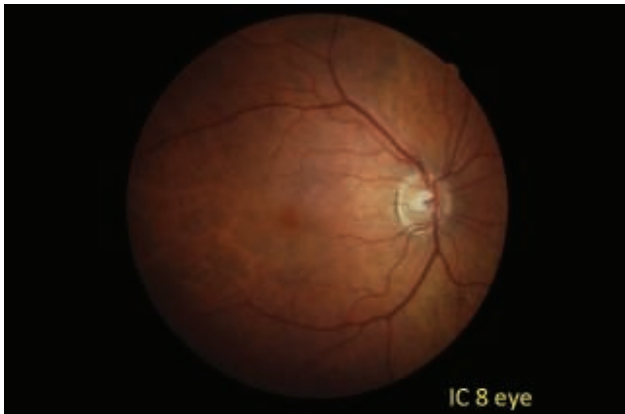

Figure 3. Peripheral light scattering is not visible with the IC-8 IOL because the mask of the IOL blocks the aberrations from the fundus view.

lens exchange with an IC-8 small-aperture IOL. Following intravitreal antibiotics, the infection and the secondary inflammation subsided. Eight weeks later, the patient underwent a pars plana vitrectomy for vitreous opacities. I was able to sit in with my retinal colleague to observe the view of the posterior segment with the IC-8 IOL in situ. A video of the procedure can be seen at eyetu.be/hncec.

My retinal colleague was able to perform core vitrectomy successfully, was able to shave off the vitreous from the peripheral retina, and was able to conduct an intraoperative examination of the peripheral retina with the IC-8 IOL in place. Although the mask of the IOL was visible, in the central field of vision, my colleague was able to work around it with the indirect viewing system off the operating microscope. By observing this procedure, I am convinced that a posterior segment surgeon can perform



WATCH IT NOW

Performing vitreoretinal surgery in an eye implanted with the IC-8 IOL.

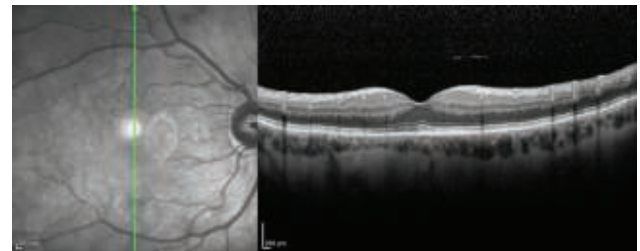
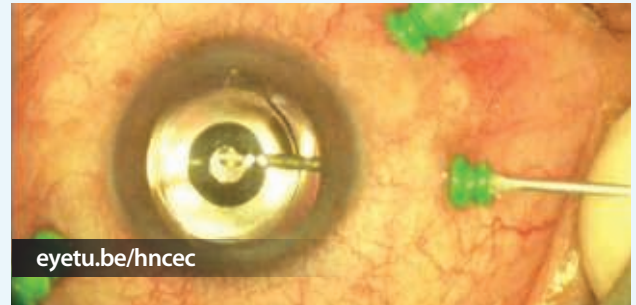

Figure 4. An uninterrupted view of the optic nerve head with the IC-8 IOL in place.

a safe and complete vitrectomy and examine the peripheral retina with the IC-8 IOL in the capsular bag.

CONCLUSION

The IC-8 IOL provides surgeons with one more option to treat presbyopia using the small-aperture optics principle. Aiming the postoperative refraction in the IC-8 IOL eye to -0.75 D seems to provide patients with enhanced intermediate and near vision without affecting binocular uncorrected distance visual acuity. Furthermore, placement of the IC-8 IOL does not affect the ability to perform subsequent retinal assessments or procedures. ■

Sathish Srinivasan, MD

- University Hospital Ayr, Scotland
- Honorary Clinical Associate Professor, University of Glasgow
- sathish.srinivasan@gmail.com
- Financial disclosure: Scientific advisory board (AcuFocus)

A Small-Aperture IOL in Post-Refractive Surgery Patients

The IC-8 IOL can be used successfully in post-RK eyes.

BY RAVI SINGH, MD



The use of multifocal IOLs in patients who have previously undergone corneal refractive surgery remains controversial. Although it is not contraindicated, implanting a multifocal IOL into an eye that likely already has increased higher-order aberrations (HOAs) after refractive surgery could negatively interact with the lens, further increasing those aberrations and producing decreased contrast sensitivity and visual quality.¹ This is of concern especially in post-RK patients if a multifocal IOL is implanted at the time of cataract surgery.

Furthermore, changes in corneal shape after corneal refractive surgery make it more challenging to pick the right IOL power. Power calculations for post-RK eyes are typically difficult, as there can be refractive changes due to the corneal instability. Key factors in IOL calculation in post-RK eyes include: (1) estimation of corneal power and (2) modified effective lens position, both of which remain a challenge in this group of patients. Unfortunately, if the lens produces a postoperative refraction outside the target range of ± 0.50 D, the patient's visual quality will suffer and negative dysphotopsia might occur if a bifocal or trifocal IOL was implanted.

In order to avoid these and other problems associated with implanting premium IOLs in post-refractive surgery patients, many cataract surgeons simply avoid multifocal and trifocal IOLs in these cases. Choosing a monofocal IOL in post-refractive surgery patients is a safer practice, as there will be fewer downsides for the patient if the target is not achieved or if the eye already presents with HOAs.

A BETTER OPTION

Conversely, the IC-8 IOL (AcuFocus) presents an opportunity to provide post-refractive surgery patients with a premium result without the unwanted visual side effects that can accompany implantation of a multifocal or trifocal IOL. The small-aperture design of the IC-8 lens works to block the mid-peripheral light rays that confuse and degrade image quality, resulting in an extended depth of focus.

For the typical cataract patient, the extended depth of focus of the IC-8 IOL results in a reduced need for spectacles and greater visual quality from near to far, without any blurry zones. In addition to these results, for the post-RK patient specifically, the IC-8 IOL can also provide relief from the glare and halos that can present from the RK cuts. This is because the mask of the lens blocks the defocused light.

TABLE 1. POSTOPERATIVE RESULTS

		UDVA	Intermediate VA @ 80 cm	Near VA @ 40 cm
1 Month Postop	OS	6/9	6/7.5	N8
3 Months Postop	OS	6/9	6/9	N8

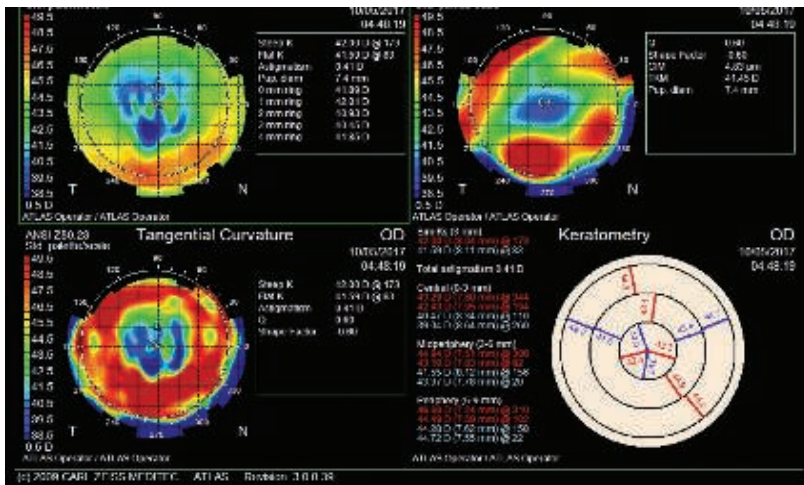


Figure 1. Corneal topography and keratometry of the patient's right eye.

Also in post-RK eyes, the IC-8 IOL provides the surgeon with a softer landing zone in terms of the refractive outcome, as the lens creates a full range of vision even if the refractive target is missed by as much as 1.00 D. The lens can also compensate for up to 1.50 D of corneal cylinder. While this does not necessarily reduce the risk of a missed refractive target, it can still provide patients with high-quality and continuous extended depth of focus.

With careful counseling of patient expectations, I believe that the IC-8 IOL is an excellent choice for the post-RK

patient. Below I share a recent case report in which I implanted the IC-8 lens into a patient who had previously undergone bilateral RK.

CASE REPORT

A 68-year-old woman presented to our clinic with visually significant cataracts on a background of having had RK surgery performed 27 years ago. She was interested in minimizing her spectacle wear post-operatively. At the patient's initial visit, BDVA was 6/9.6 in her right and left eyes, with refractions of $-0.50 +1.50 \times 172^\circ$ and $-2.50 +1.75 \times 7^\circ$, respectively. She had also experienced a myopic shift in her left eye.

The keratometry readings in the patient's right eye were K1: 40.41 D and K2: 41.45 D, and in her left they were K1: 41.02 D and K2: 41.93 D. Because the patient's left eye

was slightly worse and there had been a myopic shift, we counseled the patient that the IC-8 IOL implanted in this eye would provide her with the best vision possible. The patient agreed to the treatment, and the IC-8 lens with a power of 24.50 D and a target refraction of -0.79 D was implanted. The patient's topography of her right eye is seen in Figure 1.

After surgery, the patient was happy with her results (Table 1), especially with her visual acuity as she can read without glasses. Although early posterior capsular opacification was noticeable in the IC-8 IOL eye, the patient has undergone a Nd:YAG capsulotomy to resolve the problem.

CONCLUSION

For post-RK patients who want the benefits of a premium IOL technology, the IC-8 IOL is a good option (Figure 2). This lens can extend depth of focus and provide similar premium results as a multifocal or trifocal IOL, without the unwanted visual side effects and intolerance to any postoperative residual refractive error that is seen in the latter options. ■

1. Braga-Mele R, Chang D, Dewey S, et al for the ASCRS Cataract Clinical Committee. Multifocal intraocular lenses: Relative indications and contraindications for implantation. J Cataract Refract Surg. 2014;40(2):313-322.

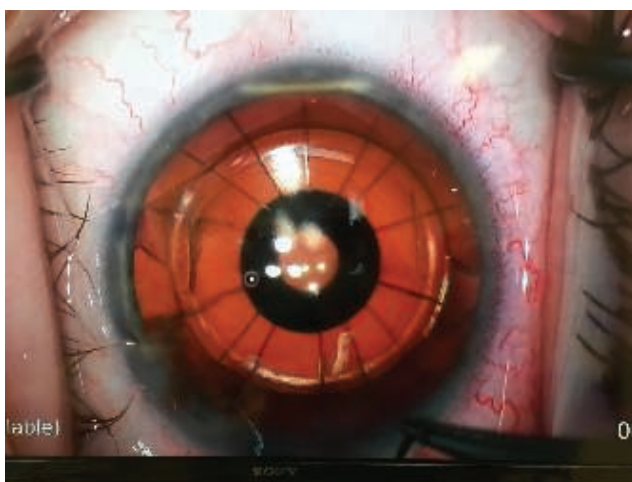

Figure 2. The IC-8 IOL implanted in a post-RK eye.

Ravi Singh, MD

- Cornea, Cataract, and Refractive Surgeon, Eye Specialists Newcastle, Australia
- isurgeons@googlemail.com
- Financial interest: None acknowledged

Simplifying Astigmatism Correction

The small-aperture optic design of the IC-8 IOL is more tolerant of cylinder than monofocal and trifocal IOLs.

BY ROBERT EDWARD ANG, MD



About 4 years ago, I started a prospective study on the IC-8 IOL (AcuFocus), a one-piece hydrophobic acrylic lens that, with the exception of a small aperture in the center of the lens, looks and feels just like any other monofocal IOL. At the start of the study in 2013, the IC-8 IOL had no dedicated injector, and the surgical technique

was to insert the lens through a scleral tunnel, without folding it, and to then suture the wound at the close of surgery. Patients received the IOL in their nondominant eye. Although surgeries were successful, patients ended up with some amount of surgically induced astigmatism (SIA) due to the scleral sutures. When we refracted patients on 1 day and 1 week postoperatively, however, we noticed that their distance vision was really excellent and they were happy with their overall visual quality (Figure 1).

The accidental realization that SIA did not greatly affect visual outcomes with the IC-8 IOL gave us a clue that the small-aperture optic of the lens might not be as sensitive to the effects of astigmatism as other IOLs, especially trifocals.

Currently the IC-8 IOL has its own dedicated injector, the width of which allows lens implantation through a 3.5-mm incision. This is still larger than other injector systems used with foldable IOLs, and some amount of SIA can still be expected postoperatively. We have continued to notice, however, that even patients with as much SIA as 1.50 D are not sensitive to its effects. I have implanted about 70 IC-8 IOLs to date, and many eyes have completed 2-year follow-up. In all cases, the results have remained consistent.

SECONDARY ANALYSIS

In a secondary analysis conducted this past year, we tested how sensitive the IC-8 IOL was to residual refractive cylinder at different powers and axes and compared it to the results obtained with a trifocal (FineVision; PhysIOL)

and a monofocal (Envista; Bausch + Lomb) IOL. This was achieved by simulating various amounts of corneal refractive astigmatism (0.50, 1.00, and 1.50 D) in specific axes of astigmatism (180° and 90°) using trial contact lenses and plotting how much it affected IOL visual acuity performance (Figure 2). Fifteen eyes in each group were included in the comparison.

We learned that, no matter the axis, each 0.50 D increase in refractive astigmatism produced increasing loss in visual acuity. At 0.50 D, there was not much drop with any of the lenses, but with 1.00 D, the loss was significant for the trifocal IOL and, to some extent, the monofocal IOL. However, regardless of axis, little effect was seen with 1.00 D cylinder

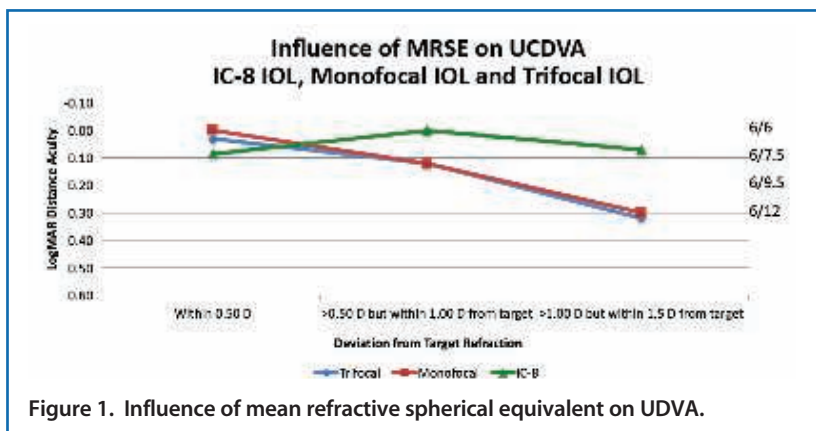


Figure 1. Influence of mean refractive spherical equivalent on UDVA.

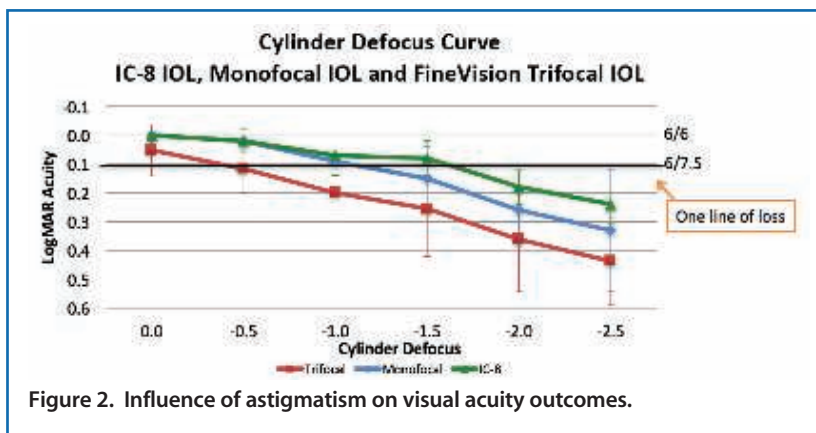


Figure 2. Influence of astigmatism on visual acuity outcomes.

in the IC-8 IOL eyes. With 1.50 D cylinder, affected distance vision was: 20/25 with the IC-8 IOL, 20/30 with the monofocal IOL, and 20/50 with the trifocal IOL. The loss in vision was linear in terms of the trifocal and monofocal IOLs and much less so in the IC-8 IOL eyes.

We believe that this finding is significant because cataract surgery will always induce some sort of astigmatism, whether regular or irregular, based on the wound size and on the phaco technique. Even applying a nomogram to account for SIA, it is still unclear how much will exactly be induced per eye. This is of utmost concern when implanting premium presbyopia-correcting IOLs like bifocal, trifocal, and multifocal lenses because SIA can cause significant patient dissatisfaction and decrease distance vision significantly.

THREE REASONS TO CONSIDER THE IC-8 IOL IN CLINICAL PRACTICE

From this study, we learned that, with the IC-8 IOL, even though some amount of astigmatism is induced during surgery, a significant effect in visual quality should not be noticeable to the patient until it exceeds 1.50 D. Therefore, in my opinion, there are three clear reasons why you should consider the IC-8 IOL in clinical practice:

1. SIA is difficult to predict;
2. The IC-8 lens can be used in place of a toric IOL for up to 1.50 D cylinder. If a patient chooses a monofocal IOL, I will only use a toric if he or she has more than 1.00 D cylinder. If the patient chooses a multifocal IOL, I take into

account lower cylinder and start recommending a multifocal toric lens at about 0.75 D cylinder. However, now I can simplify patient selection by recommending the IC-8 IOL for up to 1.50 D cylinder. I believe that this lens can easily compete with low-powered toric IOLs, specifically because it preserves distance vision but also because it extends depth of focus, providing presbyopia correction due to the small-aperture optic; and

3. The IC-8 IOL provides convenience for the surgeon and for the patient. Anyone who uses a toric IOL knows how inconvenient surgical planning is, but now this can be eliminated by using the IC-8 IOL.

CONCLUSION

In my early analysis of the IC-8 IOL, I found that it was not as sensitive to astigmatism as other lens technologies, including monofocal and trifocal IOLs. Although the IC-8 lens does not correct cylinder, it is more tolerant of the effect of cylinder. A randomized study with a larger sample size is needed to confirm this result. ■

Robert Edward Ang, MD

- Senior Ophthalmologist and Head of Cornea and Refractive Surgery, Asian Eye Institute, Makati City, Philippines
 - angbobby@hotmail.com
 - Financial interest: Clinical investigator, Consultant (AcuFocus)
-

The Challenge of Keratoconus in Cataract Surgery and the Benefits of a Small-Aperture IOL

Patients with keratoconus have responded positively to the IC-8 IOL.

BY OMID KERMANI, MD



I have been in clinical practice for more than 25 years. Over this time, because of advancements in the treatment of keratoconus, the volume of keratoplasty procedures I and others perform has significantly decreased. With that, however, comes an increase in the number of patients with therapeutically stabilized keratoconus who develop a cataract.

Because keratoconic eyes tend to have high astigmatism, one relatively successful strategy in this situation is implantation of a toric IOL. However, in addition to residual regular astigmatism, patients who have undergone CXL, intrastromal corneal ring segment implantation, or topography-guided PTK and PRK have a tremendous amount of irregular astigmatism still present in the eye. These higher-order aberrations are not addressed by a toric IOL, which only corrects lower-order refractive errors. Certainly cataract surgery will improve visual acuity; however, the retinal potential of visual acuity usually is not fully restored, and patients continue to suffer from ghosting and night vision disturbances and have difficulty reading.

A SMALL-APERTURE SOLUTION

Another option that recently came to my attention for keratoconus patients with cataracts is the IC-8 IOL

(AcuFocus), a small-aperture aspheric monofocal lens that works by the same principle as the Kamra corneal inlay (AcuFocus). Encouraged by a case report published by Schultz and Dick,¹ I have implanted the IC-8 lens bilaterally in two keratoconic patients and unilaterally, in the eye with the most pronounced cataract, in four. In those patients who received the IC-8 lens only in one eye, either a conventional IOL was implanted in the other eye or surgery has not yet occurred. By the end of 2017, we anticipate having implanted the IC-8 IOL in 10 to 12 keratoconic eyes.

Patients have responded positively to the option of a small-aperture IOL. I explain the lens' principle to them and clarify that we must wait at least 4 to 5 weeks in between eyes to ensure the lens works properly for them. I ask patients to pay close attention to any sensations that they might have with the IC-8 IOL, such as loss of visual field or if they have the feeling that the eye is darker at night. So far, none of my patients have had this problem, but a few have asked about it before surgery, and explaining this is reassuring to them. Patients as well as referring doctors need to know that checking the retinal periphery is not a problem with the IC-8 IOL in place. Angiography is also possible with the small-aperture IOL. Only the quality of the retinal OCT with some of the currently available technology may be affected.

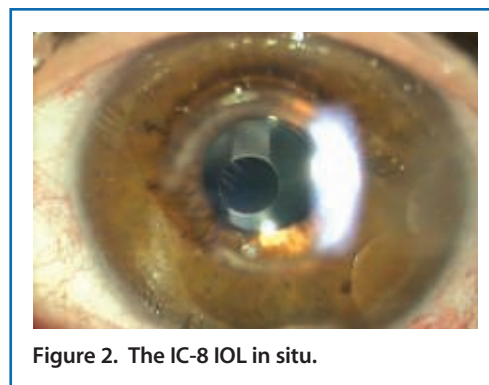
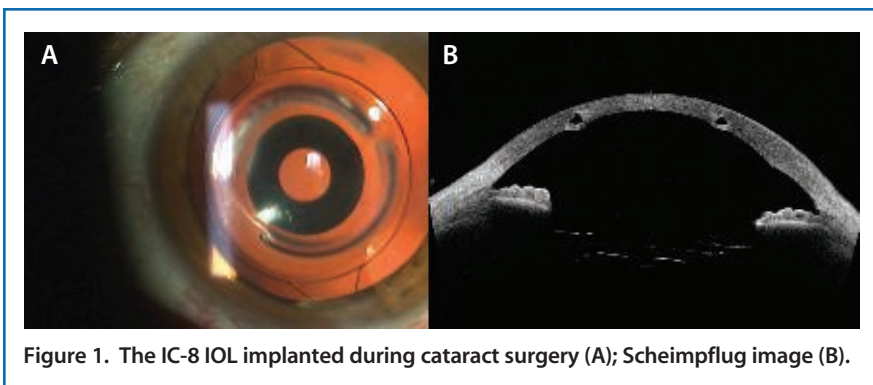


Figure 1. The IC-8 IOL implanted during cataract surgery (A); Scheimpflug image (B).

Figure 2. The IC-8 IOL in situ.

CLINICAL EXPERIENCE

In the current population of patients, we have up to 9-month follow-up. In the bilateral cases, no patient has complained about reduced visual acuity at night or loss of visual field, and significantly less ghosting with reading has been reported. In general, these patients are happy.

In the unilateral cases, responses have been similar: Patients have better vision in the IC-8 IOL eye compared with the untreated eye, and they feel that the increase in the depth of focus is rewarding. In all cases, UDVA is least 20/40. Not only is UDVA better and optical side effects of corneal aberrations are reduced, but these patients even report that UNVA is significantly improved in the IC-8 IOL eye.

I would like to share one specific case that is quite impressive. A patient with keratoconus who had intrastromal corneal ring segments (ICRS) implanted 10 years ago at another clinic presented to our clinic with cataracts. Preoperatively, refraction in her right and left eyes was $-0.25 -3.00 \times 30^\circ$ and $-7.25 -4.25 \times 73^\circ$, respectively; BCVA was 20/40 and 20/100, respectively. In her left eye, UCVA was 20/400.

My colleague Georg Gerten, MD, implanted the IC-8 IOL underneath the ICRS in her left eye, and she was able to obtain a UCVA of 20/63 and BCVA of 20/32 at 3 months postoperatively. The refraction in her left eye improved to $-2.25 -0.75 \times 173^\circ$. Figures 1 and 2 depict pretty clearly what the advantage of the IC-8 IOL is in eyes with keratoconus.

WHY IT WORKS

The cornea is the most powerful refractive surface of the eye, and therefore it can have a large effect on the quality of the image. The concept of a small-aperture IOL in the presence of

keratoconus is both logical and elegant because it cuts off the disturbing portion of the light that is aberrated by the irregular cornea. The point spread function of the retinal image is sharp, and the brain accepts the elongated focus very nicely. ■

1. Schultz T, Dick HB. Small-aperture intraocular lens implantation in a patient with an irregular cornea. *J Refract Surg.* 2016;32(10):706-708.

Omid Kermani, MD

- Medical Director, Augenklinik am Neumarkt, Cologne, Germany
- info@augenportal.de
- Financial disclosure: None acknowledged

Learn more about the **IC-8 IOL**
at **ESCRS Booth #P273**



CRST EUROPE

Cataract & Refractive Surgery Today